Neuroimaging For Psychiatrists

Never Stand Still | Medicine | Department of Developmental Disability Neuropsychiatry

Professor Julian Trollor
Chair, Intellectual Disability Mental Health
Head, 3DN
School of Psychiatry, UNSW Australia
j.trollor@unsw.edu.au

Overview

- Basics of modern brain imaging techniques including strengths and weaknesses
  - CT (computerised tomography)
  - MRI (Magnetic Resonance Imaging)
  - MRS (magnetic resonance spectroscopy)
  - SPECT (single photon emission computerised tomography)
  - PET (positron emission tomography)
- Clinical Imaging
  - When should imaging be done?
  - Which tool for which job?
  - How to read a scan
  - Determining the significance of the finding
- An Example: Cognitive Decline
- Advances & Future Developments

Computerised Tomography

- Utilises property of attenuation of x-ray beams passing through tissue
- Detectors opposite the source measure extent of this attenuation
- Limitations: spatial resolution (0.5-1cm), radiation, artefact
- Advantages: cheap, available, quick
- Good for: acute blood
- Bad for: subacute blood, posterior fossa & brainstem, small lesions

MRI: Basics 1

- Utilises inherent magnetic field produced by the nuclei of some atoms (eg hydrogen proton in H2O)
- External application of strong magnetic field causes alignment of these protons
- Disruption of this alignment occurs by application of a brief pulsed radiofrequency
- Measurement of the radiofrequency omitted as the protons realign in the magnetic field allows characterisation of different tissue

MRI: Basics 2

- Good Points
  - no radiation
  - spatial resolution
  - multiplanar imaging
  - minimal bone distortion
  - good grey/white matter differentiation
- Bad Points
  - claustrophobia, noise, lengthy
  - metal devices/fragments contraindicated
  - expense & access
  - poor at imaging blood

MRI: Multiplanar Imaging

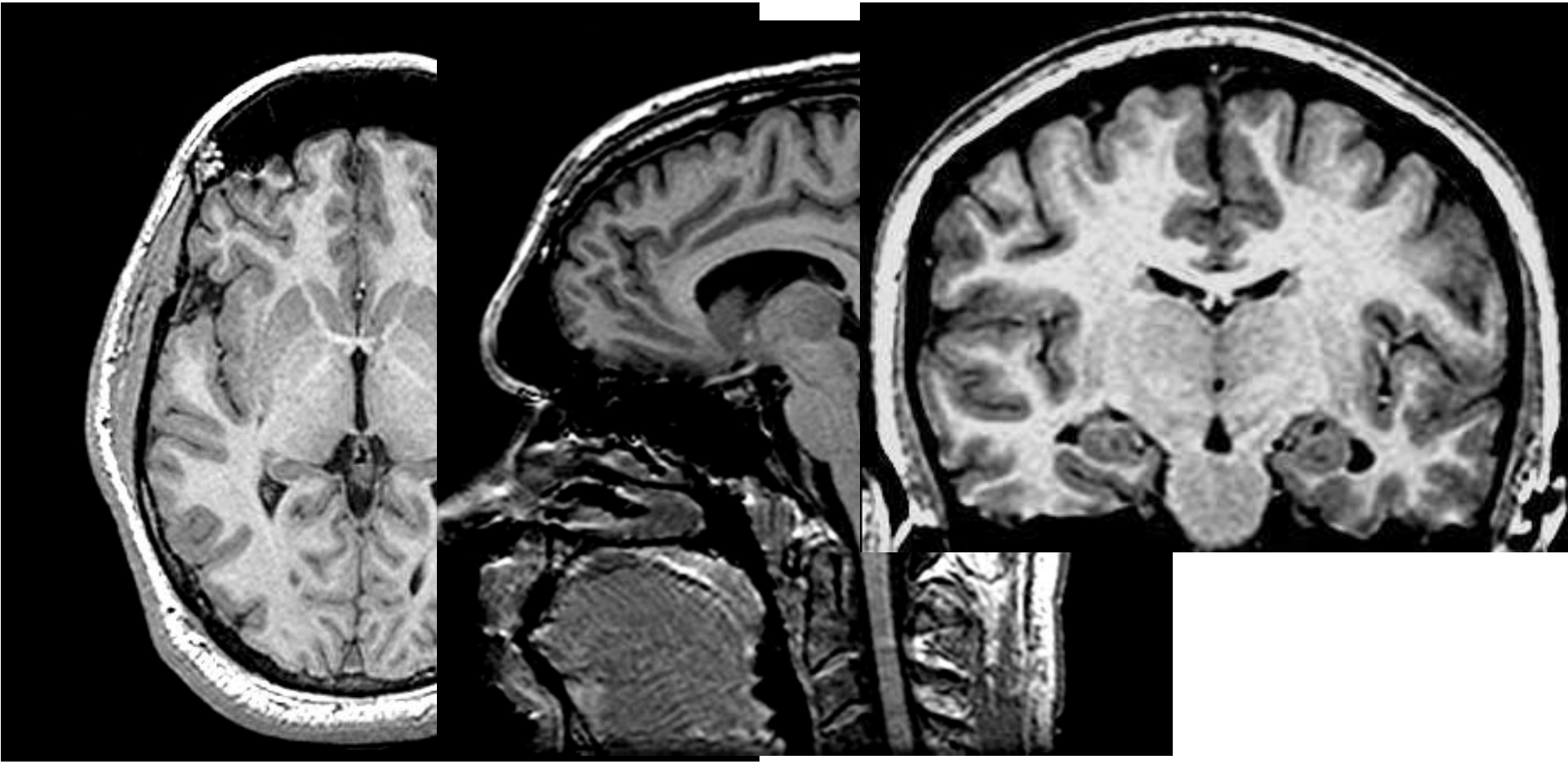

MRI: Advanced 1

- Scanning Sequences
  - TE= Echo time; TR: Repetition time
  - T1: TE<50, TR<1000; CSF dark ; +/- Gadolinium
  - T2: TE>80, TR>2000; CSF & fluid white
  - FLAIR: fluid attenuated inversion recovery; like T2 but CSF dark
  - Proton Density: TE<50; TR>2000; most pathology bright
  - Diffusion Weighted Image: low resolution, good for infarcts
  - Susceptibility weighted (SWI): microbleeds
  - MR angiogram: no contrast used

MRI: Advanced 2

- fMRI (Echoplanar): detecting a blood oxygen level dependent signal
  - ↑ blood flow due to neural activity leads to ↓ in deoxyhb
  - Magnetic properties of deoxyhb provides a natural contrast effect
  - Advantages: spatial localisation, high resolution, speed and lack of radiation exposure
  - Applications: neurosurgical planning, localisation of cognitive and perceptual functions, probing disease pathophysiology

MRI: Advanced 3

- MRS: quantification of spectra of compounds
  - 31P (phosphorus MRS): membrane phospholipids & phosphate bonds
  - 1H (proton MRS) purports to measure:
    - Neuronal viability and density [NAA]
    - Membrane synthesis and metabolism [choline, phosphocholine and glycerophosphocholine and creatine/phosphocreatine]
    - Possible glial cell markers [myoinositol (mI)]

Single Photon Emission Computed Topography: History

- 1948: Kety & Schmidt N2O to measure CBF
- 1963: Xe133, multiple detectors, separated white/grey matter-2D
- 1960's-70's: tomography (3D derived from 2D)
- 1980's: newer radiopharmaceuticals
- Better resolution, extended applications

SPECT: Principles (i)

- Creating 3D image based on distribution of radiotracer (isotope)
- Radiotracer is lipophyllic, crosses BBB, becomes trapped
- Radiotracer emits gamma rays (photon)
- Distribution reflects rCBF

SPECT: Principles (ii)

- Gamma rays emitted in all directions
- Collimator prevents non-aligned gamma rays from reaching the detector
- Line of origin of gamma rays detected
- Exact site of origin determined by rotating cameras around the body part to supply multidirectional information
- Gamma rays collide with sodium iodide crystals which emit light at varying intensity depending on the energy of the gamma ray

SPECT: Principles (iii)

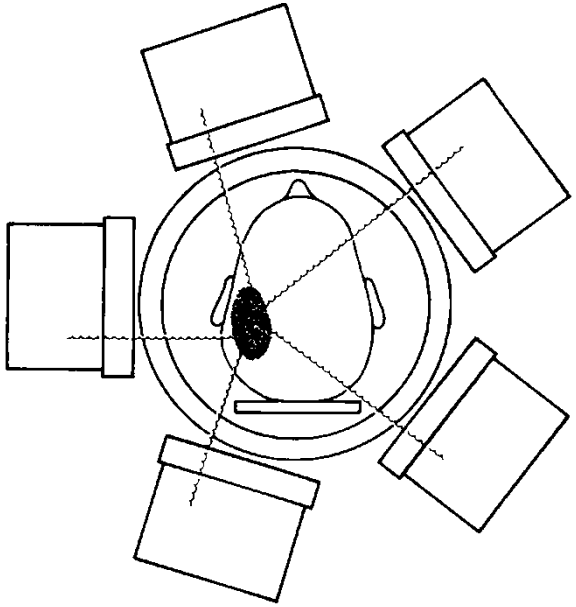

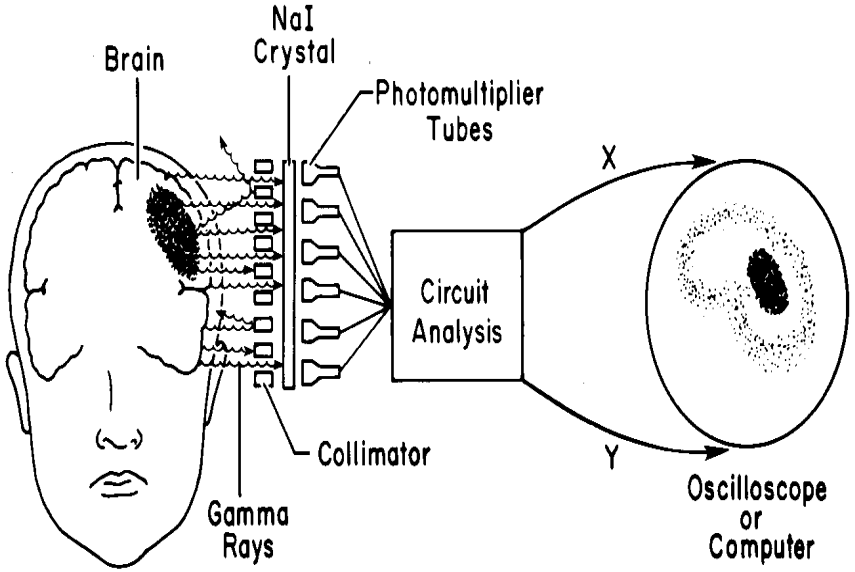

From: Andreasen NC, Brain Imaging: Applications in Psychiatry, APA, 1989.

Alzheimer's Disease: Example

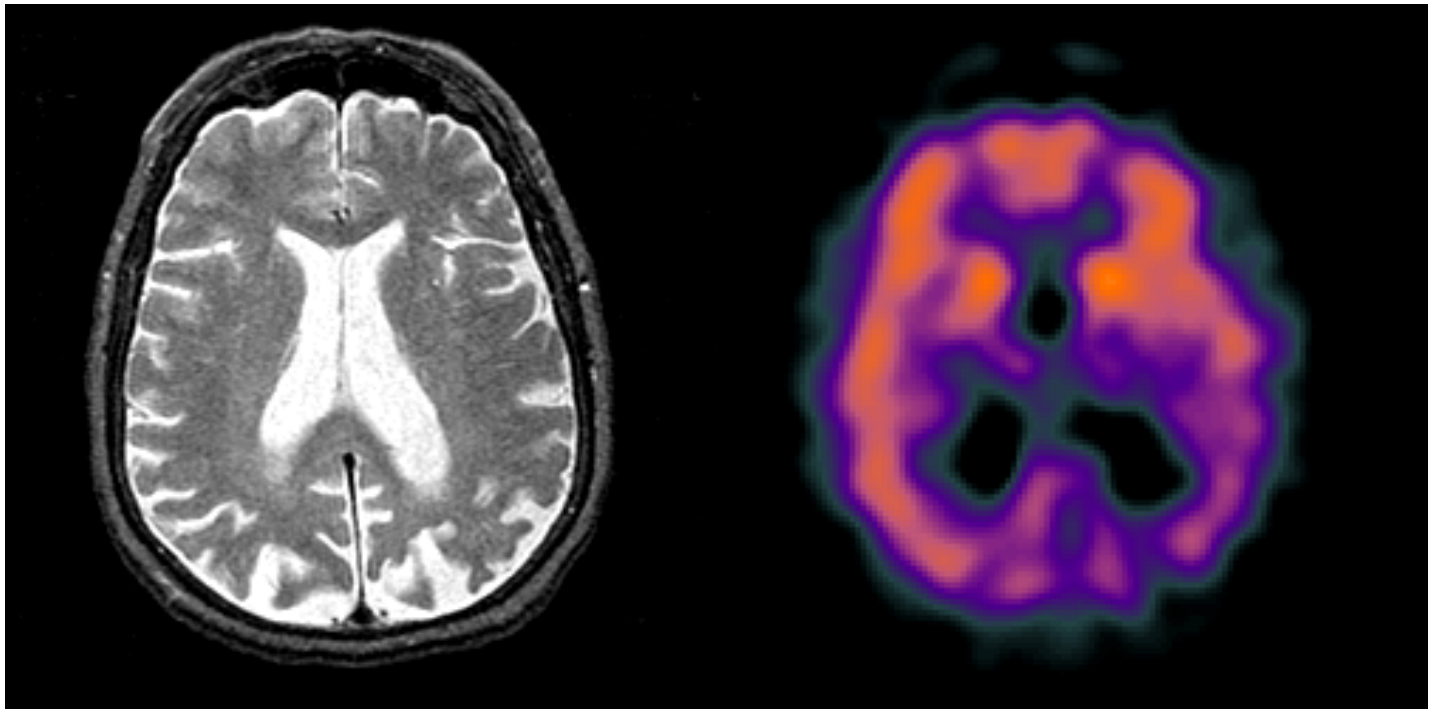

Vascular Dementia

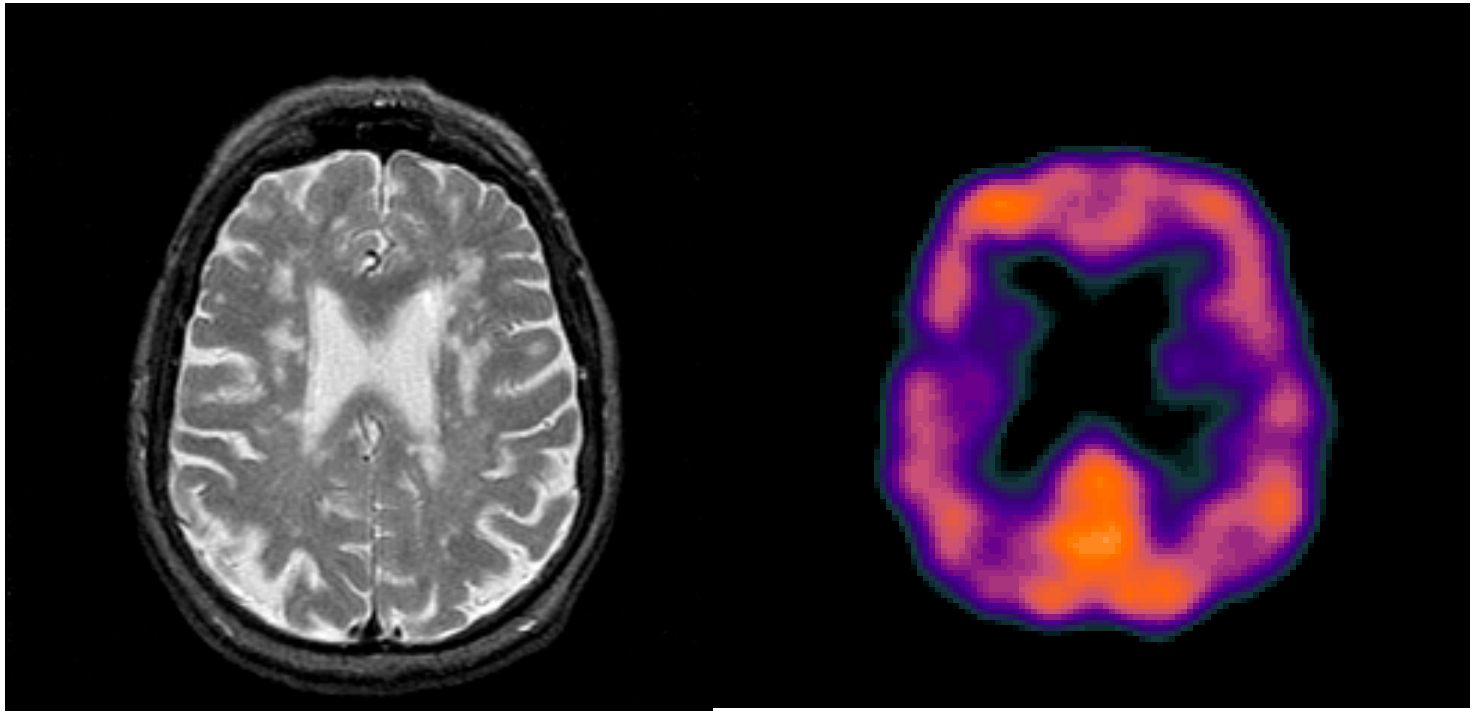

Positron Emission Tomography (PET): Principles

- First used in late 1970's
- Technique based on production of positron emitting isotope
- In a cyclotron, isotopes are bombarded with protons
- Positron has same mass as an electron but a positive charge

PET Principles (cont)

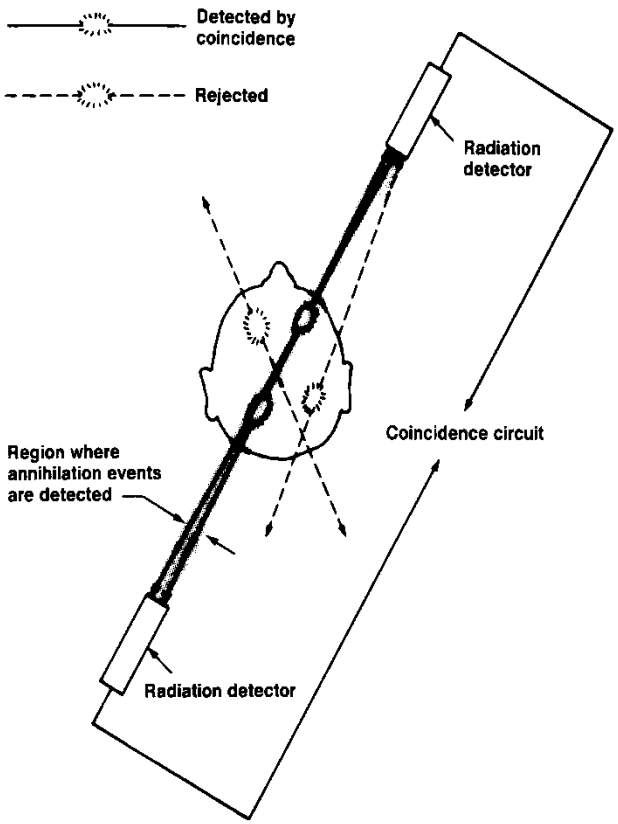

- After injection, decay of isotope, emission of positrons
- Positrons encounter electrons in tissue & annihilation takes place
- Emission of 2 gamma rays (photons) travelling at 180^0 to each other
- Coincident detection of these photons forms the basis for the detection of the PET image

From: Andreasen NC, Brain Imaging: Applications in Psychiatry, APA, 1989.

Positron Emitting Bioisotopes

Element	Isotope	$T^{1/2}$(min)
Oxygen	^{15}O	2
Carbon	^{11}C	20
Nitrogen	^{13}N	10
Flourine	^{18}F	110

^{18}FDG used to assess cerebral metabolism

^{15}O used to assess cerebral blood flow

Fronto-temporal Dementia

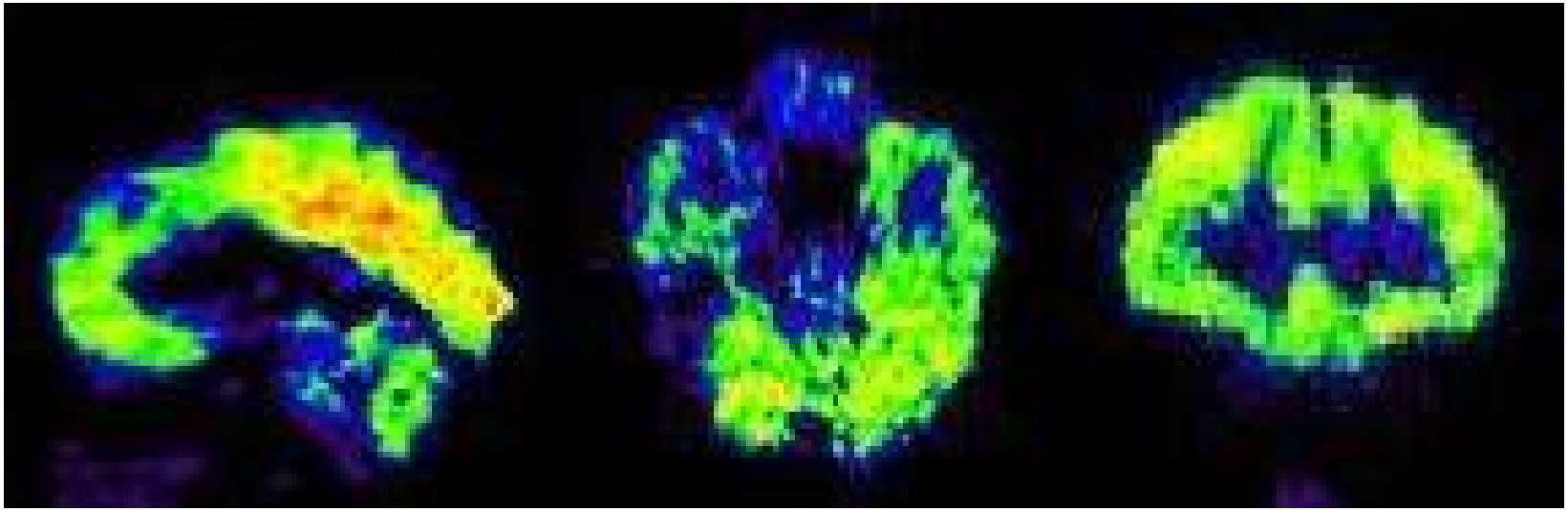

Combining information from MRI & PET can be helpful

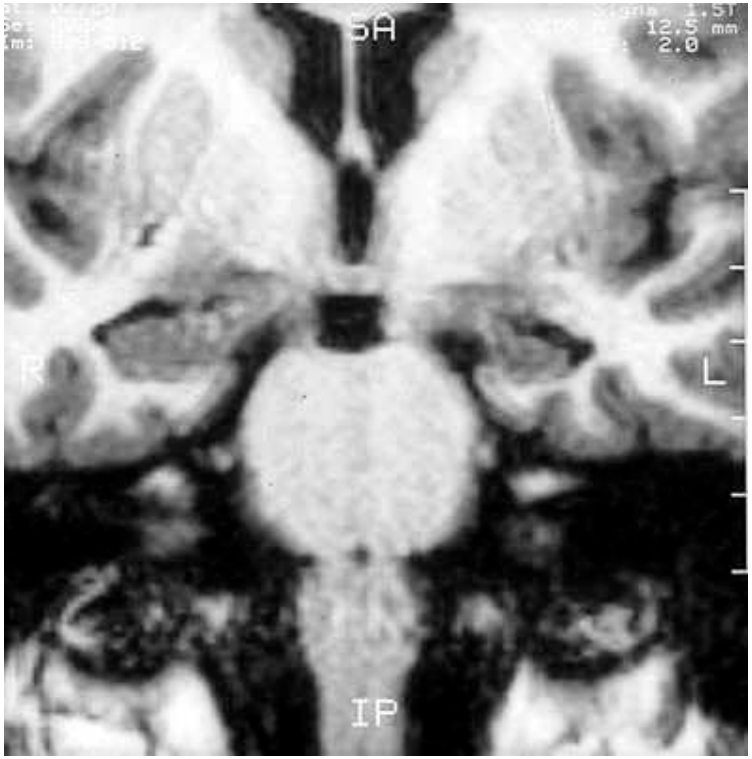

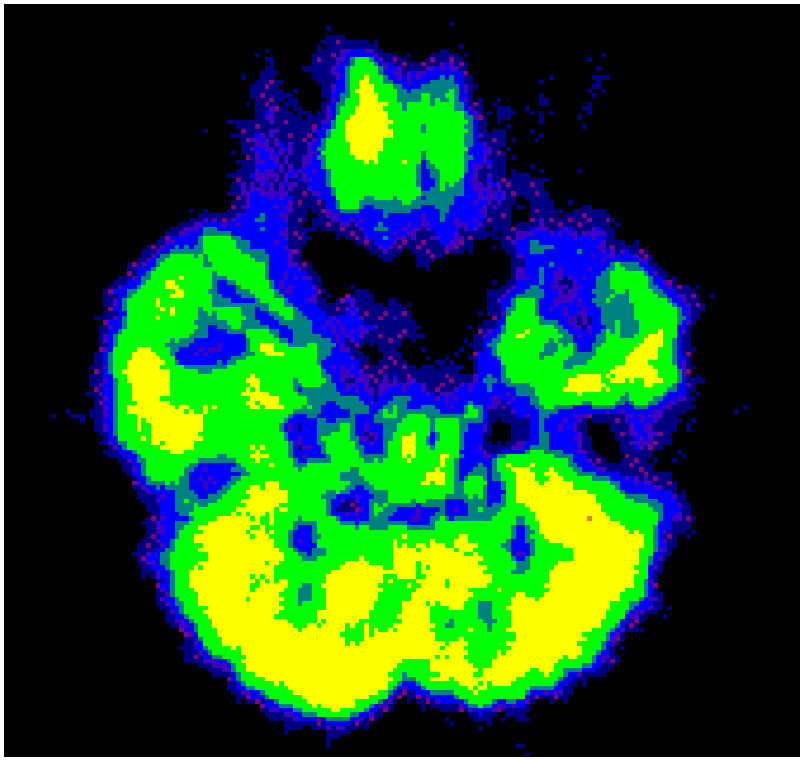

PET V'S SPECT

	PET	SPECT
RESOLUTION:	5-6mm	7-8mm
ISOTOPES:	O15, C11, F18	I123, Tc99m, Xe133
T 1/2 ISOTOPES:	2, 20, 110min	13, 6, 127hrs
PRODUCTION:	ON SITE	COMMERCIAL
COST:	$1500-2000	$400-1000

Types Of Imaging Studies

- Simple Resting Studies of rCBF or rCMRGl
- ‘Activation’ Studies
  - Motor
  - Sensory
  - Cognitive (multiple runs in PET and split dose regimes for SPECT)
  - Pharmacological
- Ligand Studies

Shortcomings of PET & SPECT

- Variable sensitivity and specificity
- Cost
- Radiation exposure
- Poor standardisation between centres
  - Variable scanning states
  - Variable resolution of scanner
  - Variable methods of image processing and analysis

Functional Imaging: Variability Of Findings

- Resolution of different scanners
- Radio-isotopes: different properties, doses
- Patient populations: variability in severity, diagnostic criteria, exclusion criteria
- Different scanning conditions: resting state v's activation, failure to control for cognitive process
- Different methods of processing/analysis

Overview

- Basics of modern brain imaging techniques including strengths and weaknesses
  - CT (computerised tomography)
  - MRI (Magnetic Resonance Imaging)
  - MRS (magnetic resonance spectroscopy)
  - SPECT (single photon emission computerised tomography)
  - PET (positron emission tomography)
- Clinical Imaging
  - When should imaging be done?
  - Which tool for which job?
  - How to read a scan
  - Determining the significance of the finding
- An Example: Cognitive Decline
- Advances & Future Developments

When to Image

- Assessment of suspected psychiatric disorder
- Atypical history or progression of psychiatric disorder
- Trauma or insult
- Diagnosis and progression of neurological disorders

Which Tool To Use

- CT without Contrast
  - Bleeds, old infarcts, hydrocephalus, cerebral oedema, skull fractures, calcification, metallic foreign bodies.
  - Avoid in pregnancy
- CT with contrast
  - Tumour, abscess, meningeal inflammation
  - Not in patients with renal failure or allergy
  - Avoid in pregnancy

Which Tool To Use

- MRI without contrast
  - Posterior fossa lesions
  - Small lesions
  - Discriminating old from new CVA's
  - Evaluating extent and severity of white matter lesions
- With Gadolinium
  - Good for inflammation, tumours
- Not with pacemaker, other metallic foreign bodies or implants; not good for unstable patients

Which Tool To Use

- SPECT/PET
  - Diagnostic difficulty for degenerative disorders
  - Localisation of lesions or seziure focus
  - Assessment of trauma (acute and resudual effects)
  - Interesting research tools

Reading a Structural Scan

- “But I’m not a neuroradiologist”
- Look at the scan
- General impression
  - Generalised cortical atrophy
  - Specific regional cortical atrophy
  - Subcortical structures including white matter loss
- Specific abnormalities: strokes, other lesions
- Compare imaging sequences for contrasts (MRI)

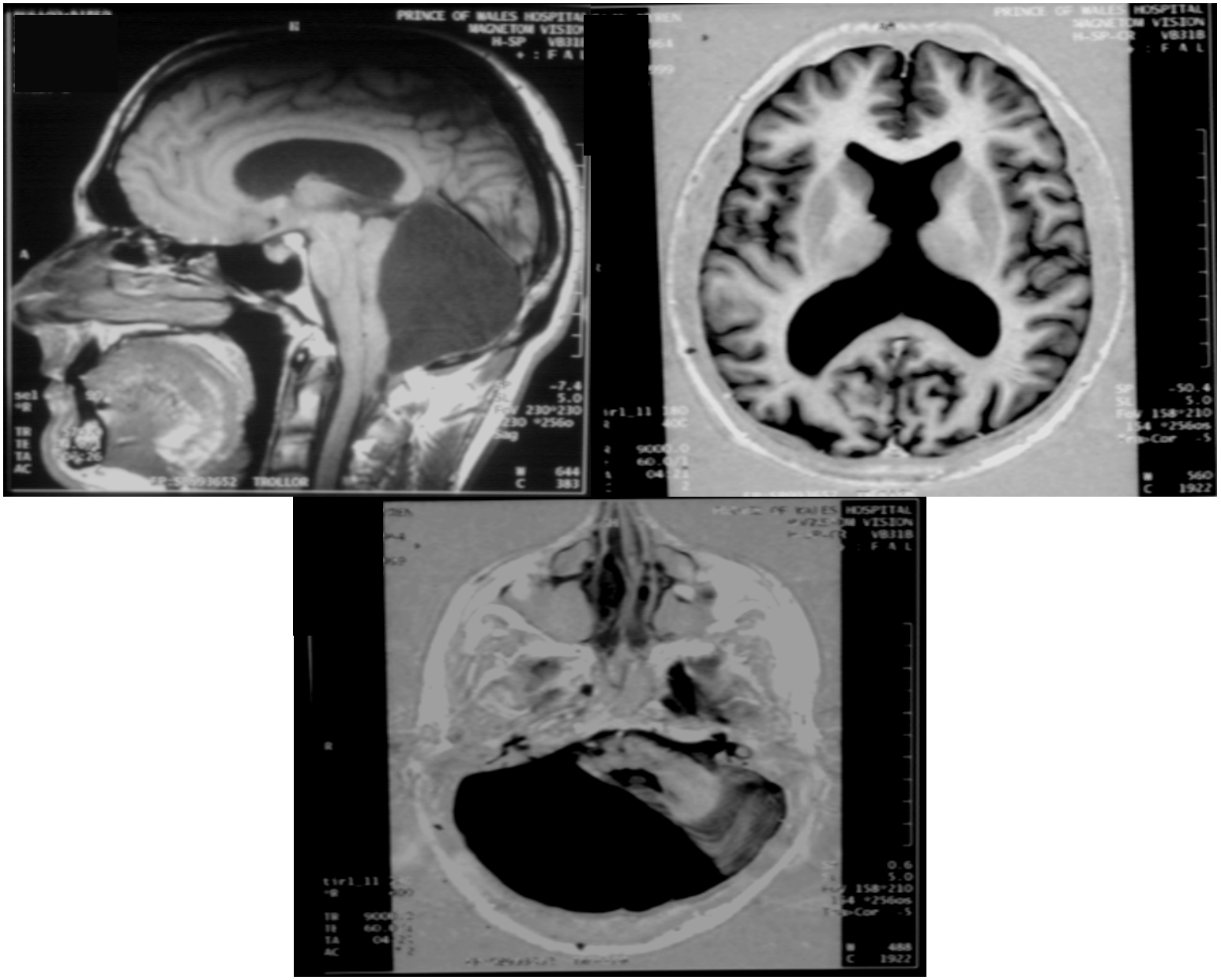
PRINCE OF WALES HOSPITAL
MAGNETOM VISION
TROLLOR
PRINCE OF WALES HOSPITAL
MAGNETOM VISION

Reading a Functional Scan

- Images printed or on disc are usually summary only and not suitable for interpretation.
- Images available on line are usually more comprehensive
- If reviewing yourself, need to be at the console with the nuclear physician
- Must fit the finding with the clinical information

Determining the Significance

- Need to know what is normal
- Age effects
- Integrating findings with clinical picture

What is "Normal": MRI

- Age
- Separating old from new eg Neurodevelopmental Insults
- Interpretation must take into account clinical information

Normal Ageing: Structural

- Ventricular size
  - ↑ with age: av. rate of increase 3% per year
  - Nonlinear ↑ VBR from 2% to 17%
  - However, clinically rated atrophy is not an inevitable consequence of age

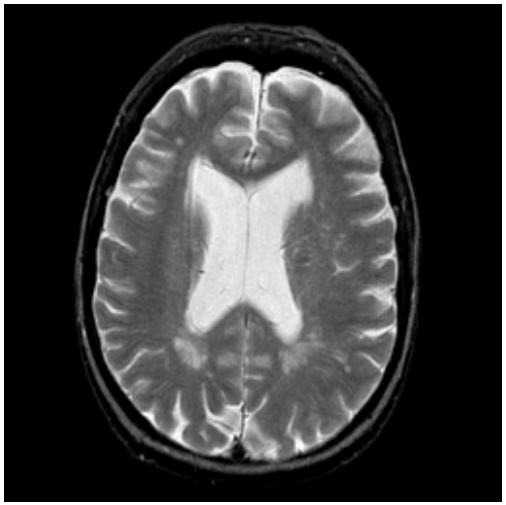

Normal Ageing: Structural

- ↓ Total Brain Volume
- ↓ Reduced Regional Volumes
  - Gray matter
  - Basal ganglia
  - Hippocampus
  - Corpus callosum
  - Frontal lobes

Normal Ageing: Structural

- Coffey et al '92

Age	% without Vent enlargement	% without Cortical Atrophy
40-49	89	89
50-59	82	82
60-69	71	59
70-79	42	38
80+	0	17

Normal Ageing: Structural

- Subcortical Hyperintensities
  - ↑ number and severity on MRI
  - Correlate with CT appearance of decreased density of white matter
  - Most commonly DWM, less commonly PWM or basal ganglia

Normal Ageing: Deep White Matter Lesions

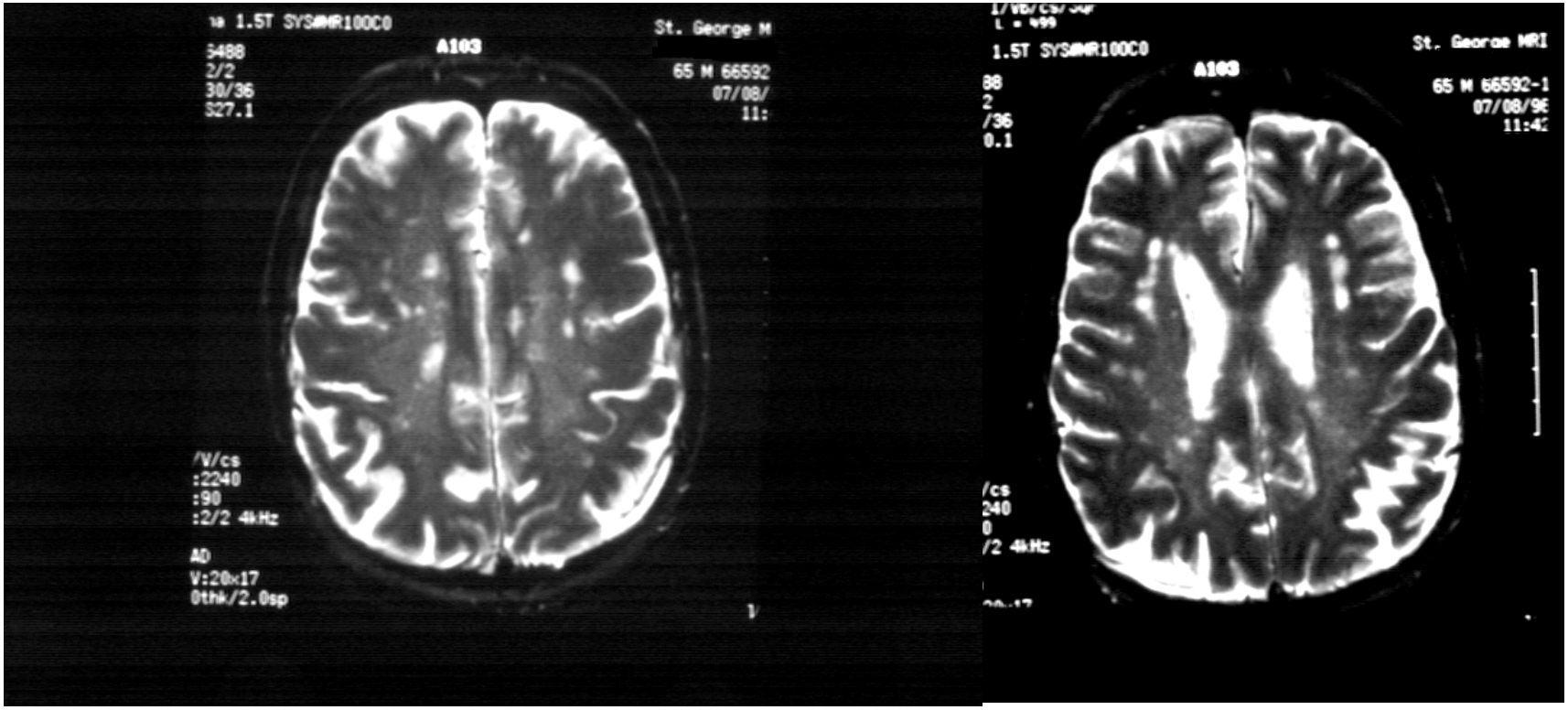

Normal Ageing: Periventricular Hyperintensities

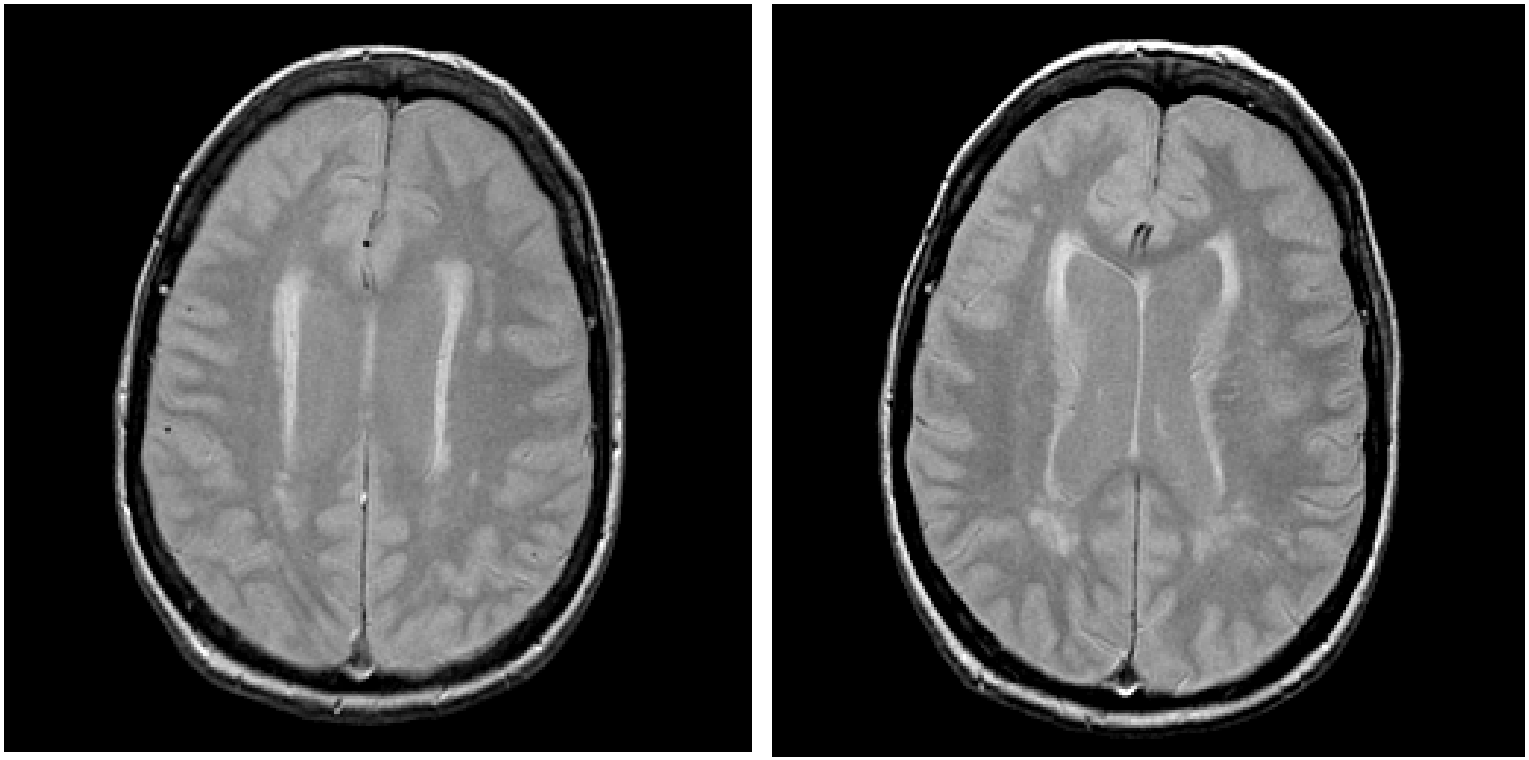

Normal Ageing: Structural

- Significance of SH'S
  - PV caps/rims: thought to be multifactorial
    - Loss of ependymal cells, ↓ myelin density, increased H2O content
    - Unclear significance
  - Severe SH: probably vascular
    - Perivascular spaces
    - Oedema
    - Infarction
    - Demyelination

What is "Normal": SPECT & PET

- Age:
  - Small reduction in rCBF and rCMRGlu, especially frontal lobes.
  - Some patchiness with age related vascular changes
  - ↑ oxygen extraction

Normal Ageing: Example

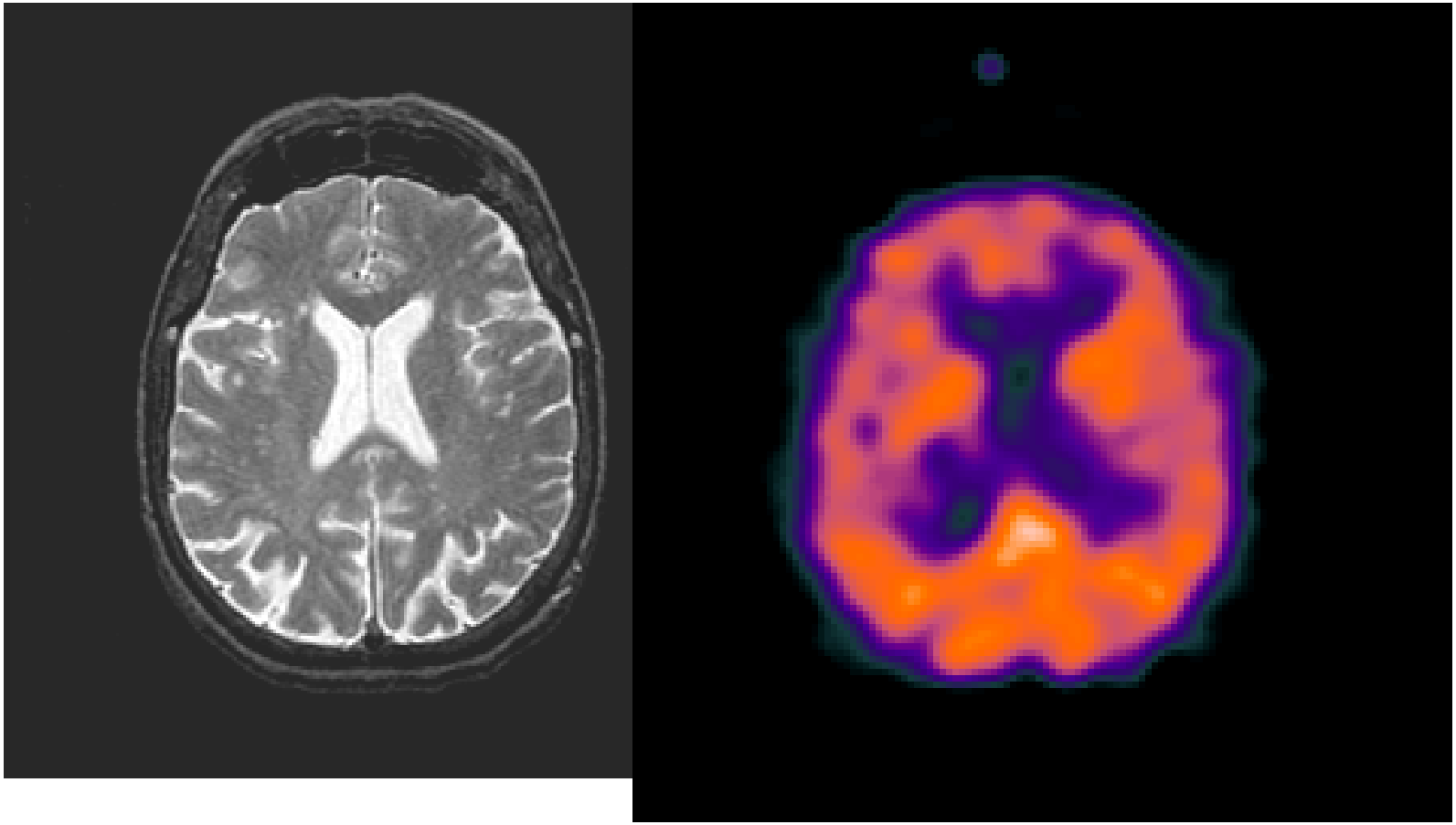

Case Vignette 1

- A 55 year old woman with a history of steadily progressive cognitive decline over a 2 year period
- A family history of ‘senile chorea’ & ‘dementia’ in mother who died at age 70
- Personal history of hypertension, an ex smoker

Case Vignette 1 (cont)

- Insidious onset and progression
- Vascular risk factors had been controlled
- Neuropsych deficits
  - Verbal and visual memory, verbal generativity, constructional and praxis
- Bloods: ApoE e4 positive

MRI

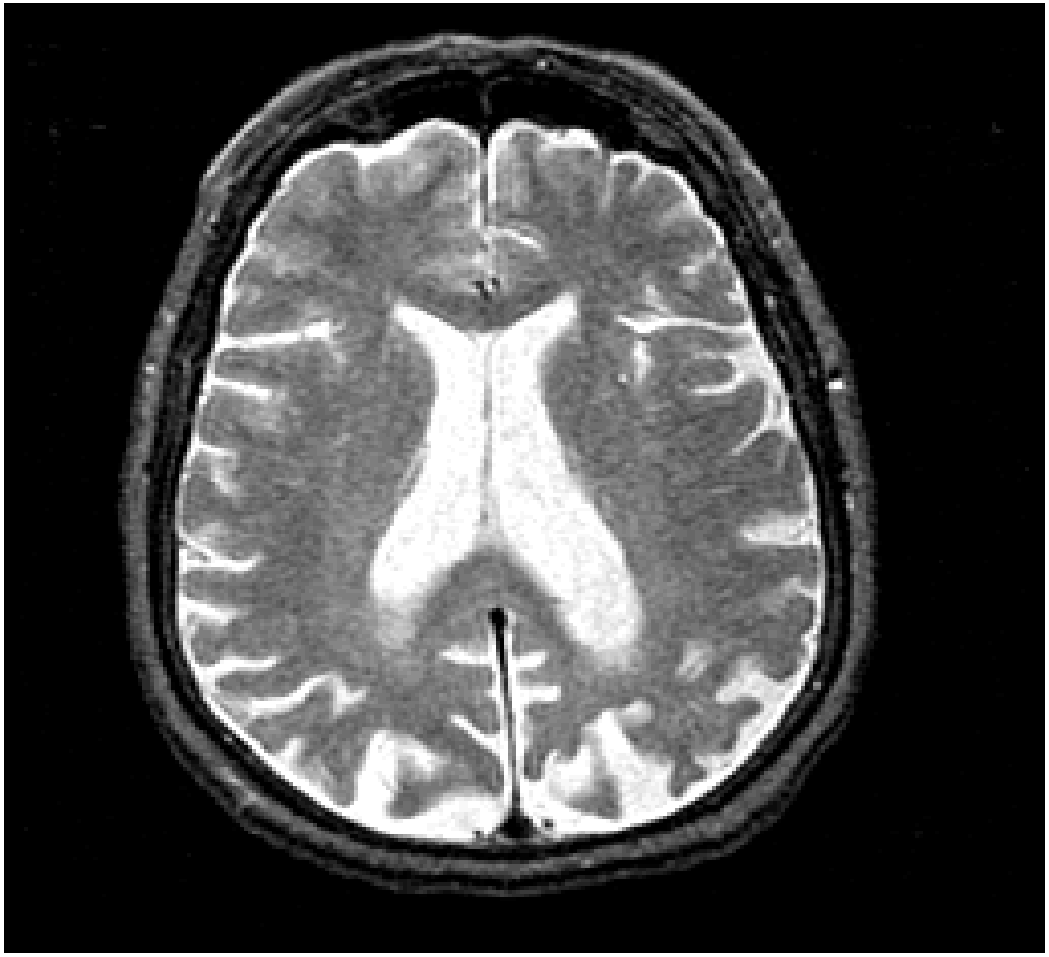

Resting SPECT

Healthy Subjects

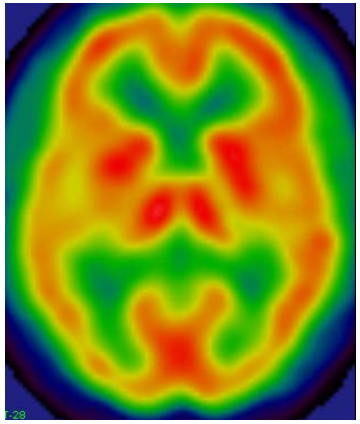

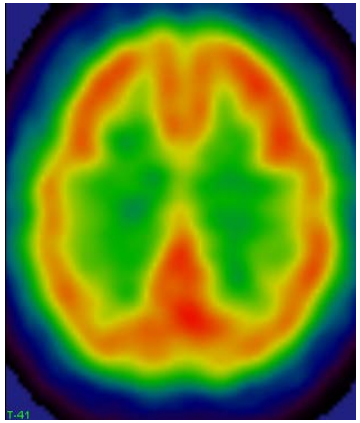

Vignette

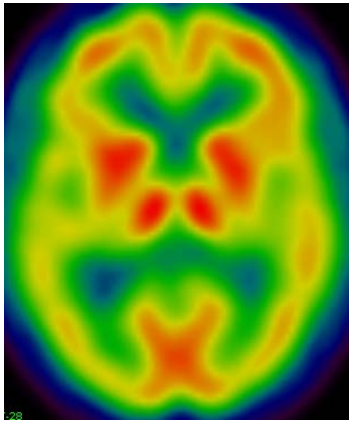

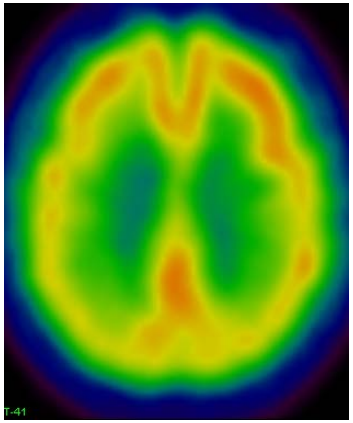

CT: Utility

- Helps exclude SOL, NPH, cerebrovascular disease
- Look at pattern of atrophy: generalised atrophy (AD); focal atrophy; head of caudate
- Increased diagnostic accuracy above clinical examination alone
- Temporal lobe orientation of scan may improve sensitivity & specificity (Jobst)
- Utility: initial screening; following progress in atypical cases

MRI: Utility

- Improved visualisation of:
  - Basal structures
  - Demyelination and inflammation
  - Vascular lesions, white matter
- Clinical utility:
  - Atypical cases
  - Diagnostic uncertainty: eg VaD v's AD
  - Focal lesion suspected

Utility of PET & SPECT Imaging in Dementia

- Cross-sectional Diagnostic Assessment
  - Atypical cases/diagnosis unclear
  - Lack of guidance from structural imaging
- Longitudinal Assessment
  - Diagnostic in unclear or early cases
  - Follow progression

‘Patterns’ in Functional Scans

- Regional Cortical rCBF/rCMRGlu
  - ↓ uptake in posterior temporal and inferior parietal regions suggests AD
  - ↓ uptake in occipital association cortex suggests DLB
  - ↓ uptake in frontal & anterior temporal cortex suggests FTD
  - Other dementias less specific
- Subcortical: reduced striatal rCMRGlu supportive of HD

OTHER DEMENTIAS

- Findings often lack specificity
- Pick's Disease, FLD & Motor Neurone Disease
  - CT/MRI: frontal atrophy
  - PET/SPECT: bilateral frontal hypoperfusion
- Huntington's Disease
  - CT/MRI: early caudate atrophy
  - PET: ↓ of 18FDG activity in the striatum may predate symptomatology

Other Dementias

- ADC
  - May show PET or SPECT abnormalities in the absence of structural changes
- Lewy Body Dementia
  - May mimic AD in structural and functional changes
- Parkinson's Disease: variable findings
  - CT/MRI: generalised atrophy; subcortical atrophy, lateral ventricle width & frontal atrophy correlate with cognitive impairment
  - PET: Global ↓ in metabolism, esp frontal (18FDG)

Vascular Dementia

- CT/MRI
  - MRI superior in identifying extent/pattern of vascular disease
- PET/SPECT
  - Patchy Radiotracer uptake
  - Overlap with other groups:
    - o Normal aging
    - o Mixed AD/VaD

Vascular Dementia: Example

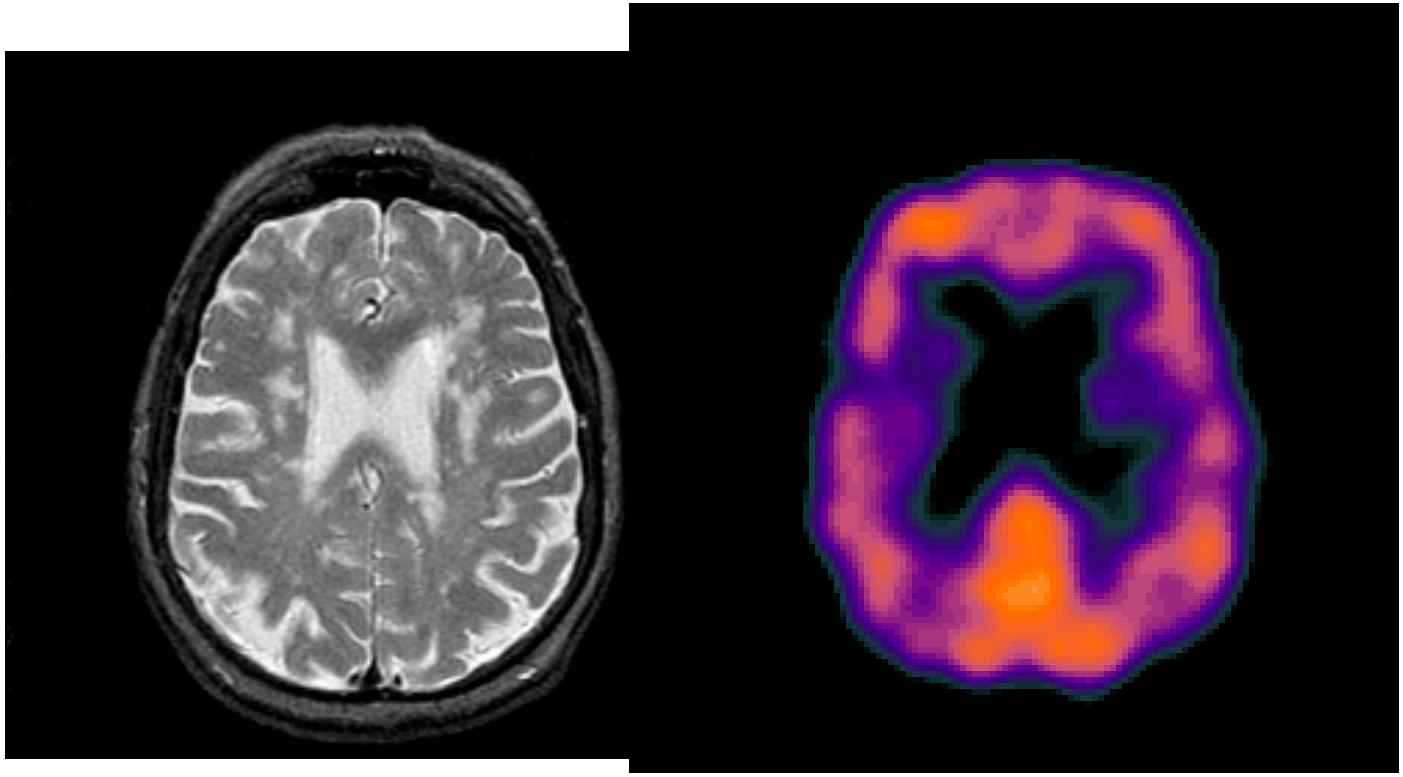

Types Of Functional Imaging Studies

- Simple Resting Studies of rCBF or rCMRGl
- ‘Activation’ Studies
  - Motor
  - Sensory
  - Cognitive (multiple runs in PET and split dose regimes for SPECT)
  - Pharmacological
- Ligand Studies
- Research
  - Clinical: functional correlations
  - Response to therapies and experimental drugs
  - Challenge with cognitive paradigm: cognitive models of disease.
  - Pathological substrates (amyloid, receptor ligands etc)

Advances in Structural Imaging

- Change in volume with time
  - Cortical, subcortical or lesions
  - Creating maps of tissue loss
- Magnetic resonance spectroscopy (MRS)
  - Brain biochemistry in neuropsychiatric disease
- Functional MRI (fMRI): location of motor strip, cognitive paradigms
- White matter integrity: Diffusion maps
- Microbleeds: using susceptibility weighted images

Volume Based Morphometry

- Inspection
- Segmentation
- Register to a template
- Spatial Normalisation
- Regress brain volumes on other biological data of interest
- Statistical correction fro multiple comparisons

Example: Inflammatory Markers and GM Volumes

Table 3 Anatomical region and MNI coordinates of peak voxels within the suprathreshold clusters correlated with inflammatory factors

IF	Cluster-level		Voxel-level				
	p (corrected)	size (n)	MNI coordinates			T value	Anatomical location (BA)
			X	Y	Z		
TNF-α	<0.001	5931	22	62	30	4.06	R superior frontal gyrus (9)
			-24	4	58	4.05	L middle frontal gyrus (6)
			4	20	66	4.02	R supplementary motor area (6)
	0.002	767	-54	-44	0	3.23	L middle temporal gyrus (22)
			-44	-60	-4	2.88	L inferior temporal gyrus (37)
			-40	-70	4	2.76	L middle occipital gyrus (19)
	0.012	850	-54	-22	24	3.77	L supramarginal gyrus (40)
			-62	-20	34	3.25	L inferior parietal gyrus (40)
			-68	-20	16	3.04	L parietal operculum (40)
IL-1β	0.004	1433	-34	-84	34	3.79	L precuneus (19)
			-52	-72	6	3.53	L middle occipital gyrus (19)
			-44	-78	26	3.05	L inferior parietal lobule (39)
VCAM	0.004	604	-2	26	28	3.04	L anterior cingulate gyrus (32)
			6	38	26	2.70	R anterior cingulate gyrus (32)
PAI-1	0.035	845	6	-66	-16	3.82	R cerebellar vermis
			12	-76	-22	3.38	R cerebellum
			-4	-56	-4	3.19	L cerebellum
	0.038	643	-36	12	-24	3.44	L temporal pole (38)
			-42	6	-28	3.13	L middle temporal gyrus (21)
			-26	-6	-34	2.87	L parahippocampal gyrus (28)

Example: Subjective Cognitive Complaints

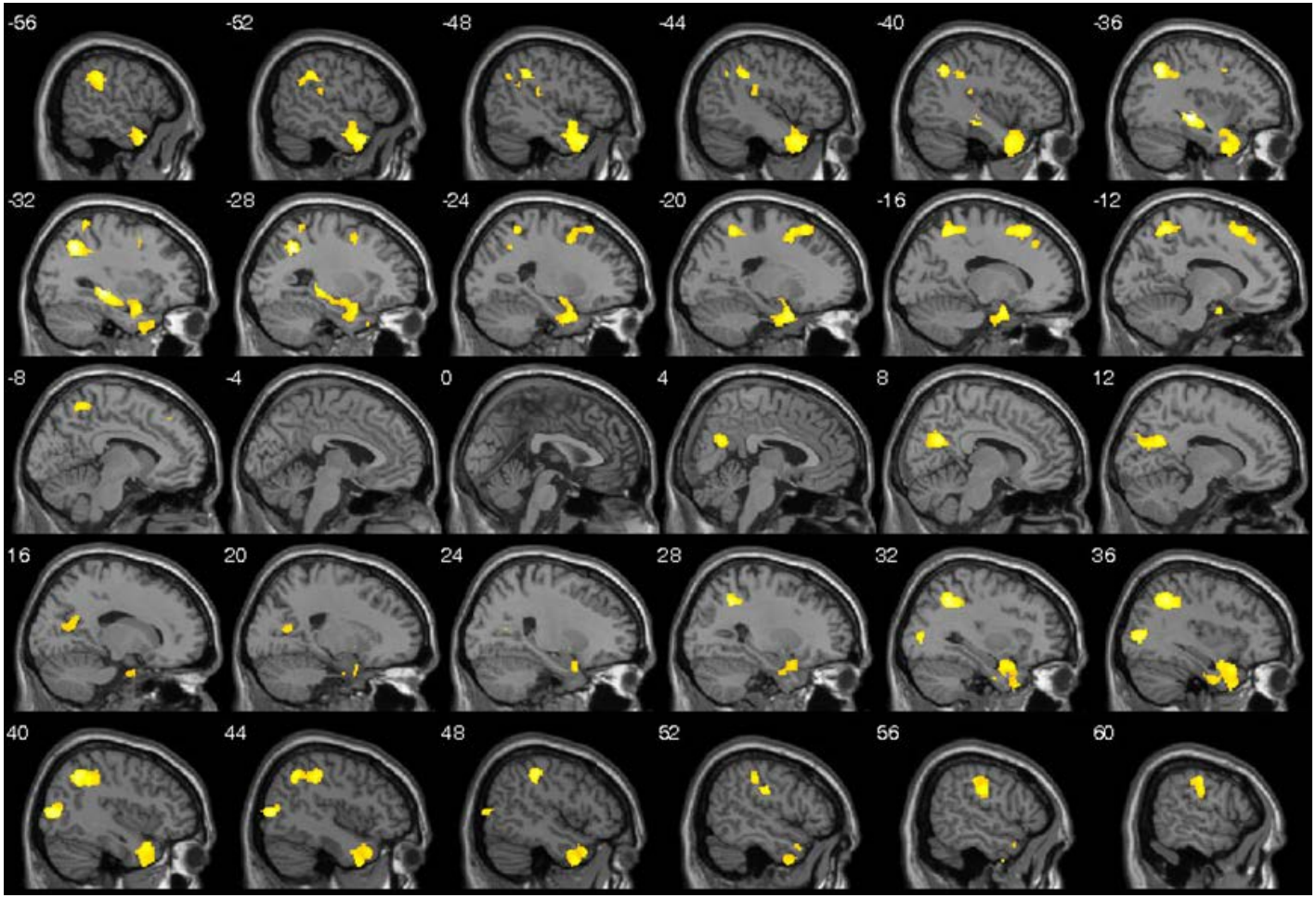

Gray matter atrophy associated with Mild Cognitive Impairment

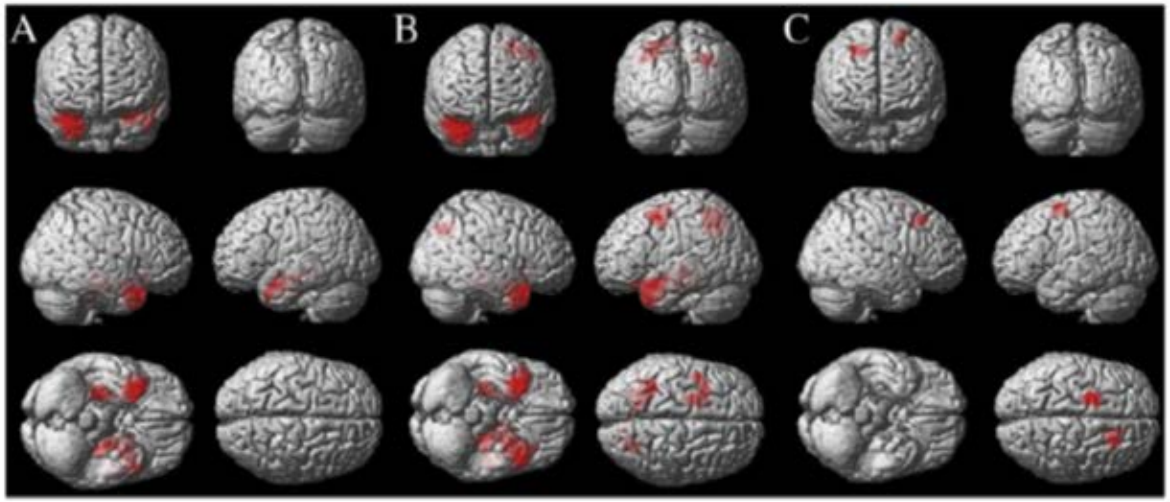

Fig. 1. Voxel-wise GM volumes were compared between aMCI subtypes and the normal control group. The brain regions, in which GM volumes were significantly different between aMCI subtypes and normal controls, were superimposed upon a rendered 3D standard brain template. The significance level was set at voxel-level inference of $p<0.005$ (uncorrected) combined with cluster-level inference of $p<0.05$ (FWE-corrected). The controlled covariates included age, sex, years of education, total intracranial volume, scanner, cardiovascular risk score (CVR), and handedness. (A) aMCI<normal controls; (B) aMCI-MD<normal controls; (C) aMCI-MD<aMCI-SD.

Journal of the Neurological Sciences
Volume 315, Issue 1-2, 15 April 2012, Pages 26-32

Neuroanatomical correlates of cognitive performance in late life

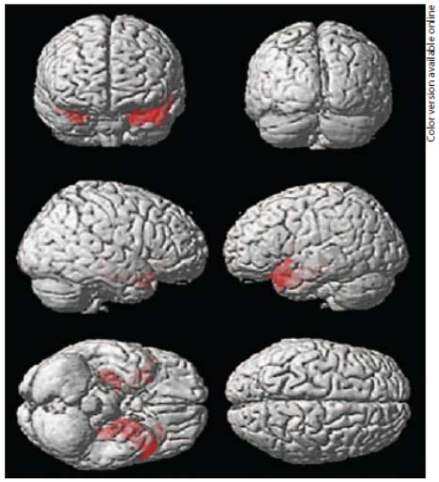

Color version available online

Fig. 1. Brain areas where the GM volumes are significantly positively correlated with the performance of the language domain, superimposed on a 3D brain template.

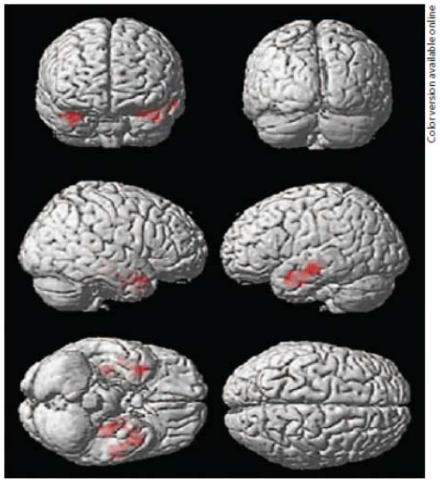

Color version available online

Fig. 2. Brain areas where the GM volumes are significantly positively correlated with the performance of the verbal memory domain, superimposed on a 3D brain template.

Color version available online

Fig. 3. Brain areas where the GM volumes are significantly positively correlated with the performance of the processing speed domain, superimposed on a 3D brain template.

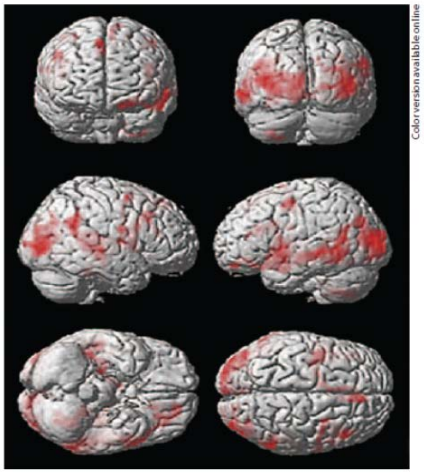

Color version available online

Fig. 4. Brain areas where the GM volumes are significantly positively correlated with the performance of the executive function domain, superimposed on a 3D brain template.

Dementia and Geriatric Cognitive Disorders
Volume 32, Issue 3, December 2011, Pages 216-226

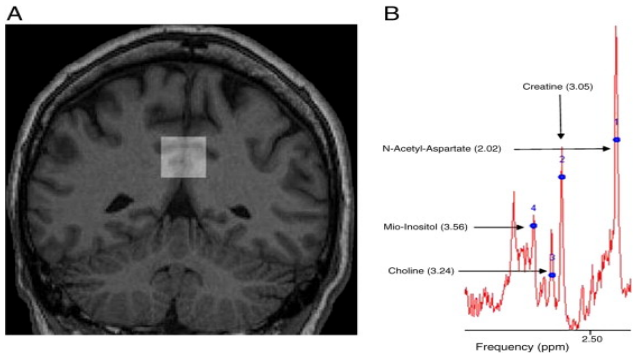

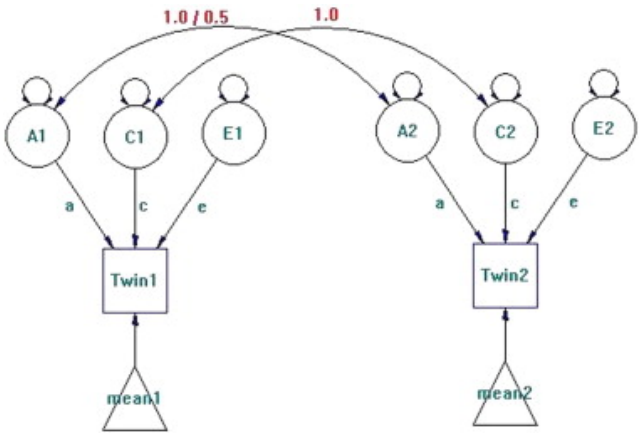

Fig.2 The path diagram for the genetic and environmental influences on a phenotypic variable in twins.

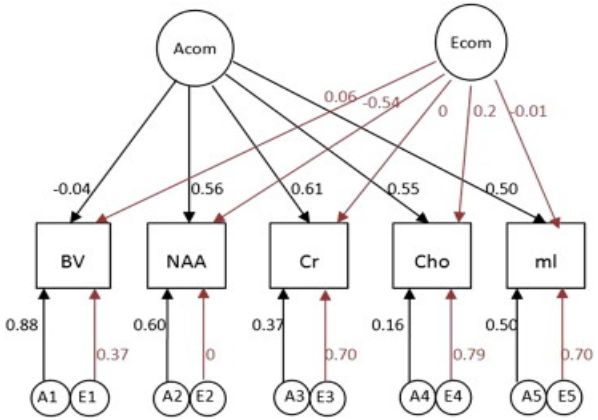

Fig.3 The multivariate IPM (independent pathway model), including the BV and the four metabolite ratios to water as variables.

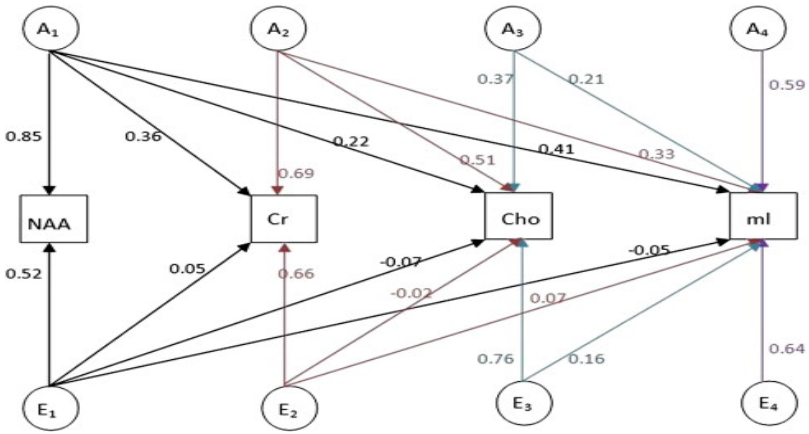

Fig. 4. The multivariate Cholesky model between the four metabolite ratios to water

The heritability of brain metabolites on proton magnetic resonance spectroscopy in older individuals

NeuroImage Volume 62, Issue 1 2012 281 - 289

DTI Analysis

- Correct for head movement and eddy current
- Strip Skull
- Fit to model
- Compute FA (Fractional anisotropy map), RD (Radial diffusivity) and AxD (axial diffusivity) maps
- Identify tract using anatomical information (or can be done in whole brain using tract based spatial statistics)
- create and place mask
- extract values

Fig. 2. 3D reconstruction of the probability maps of the fornix and corticospinal tract from all subjects. In the top panel, the purple color indicates the right fornix, and the green color represents the left fornix. In the bottom panel, the corticospinal tract was shown in red. Both the fornix and corticospinal tract were overlaid on a 3D rendering of the MNI T1 template.

Sulcal morphometry

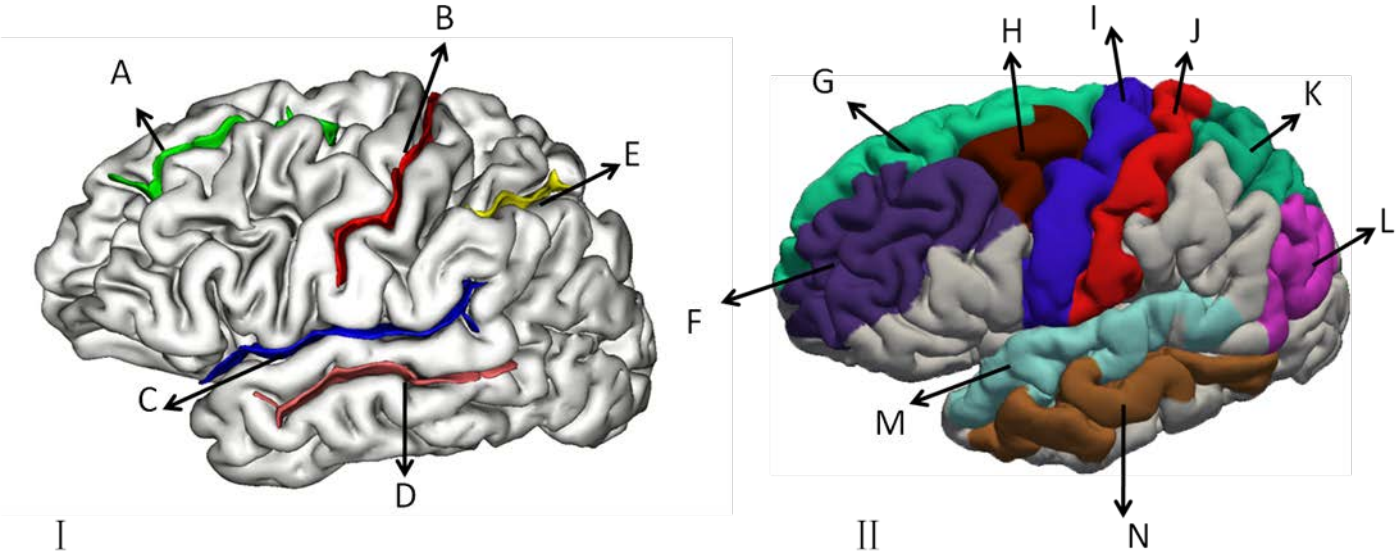

The relationship between cortical sulcal variability and cognitive performance in the elderly

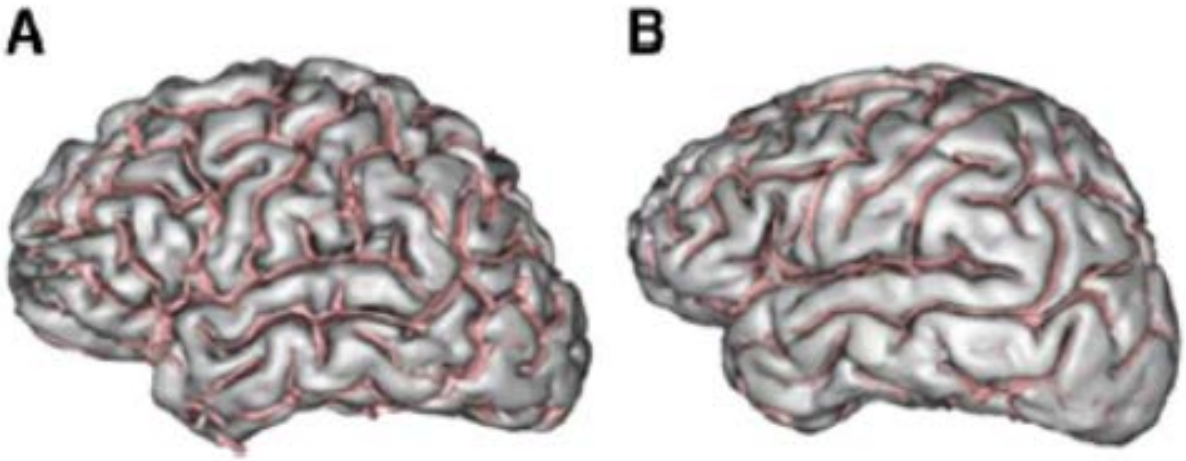

Fig. 1. The global sulcal index (g-SI) for each hemisphere is measured as the ratio between the total sulcal area and the outer cortex area. Two participants illustrate (A) a high and (B) a low overall g-SI.

NeuroImage
Volume 56, Issue 3, 1 June 2011, Pages 865-873

Figure 2.Interrelationships of two-year changes among sulcal width, cortical thickness, subcortical, white matter and grey matter volumes

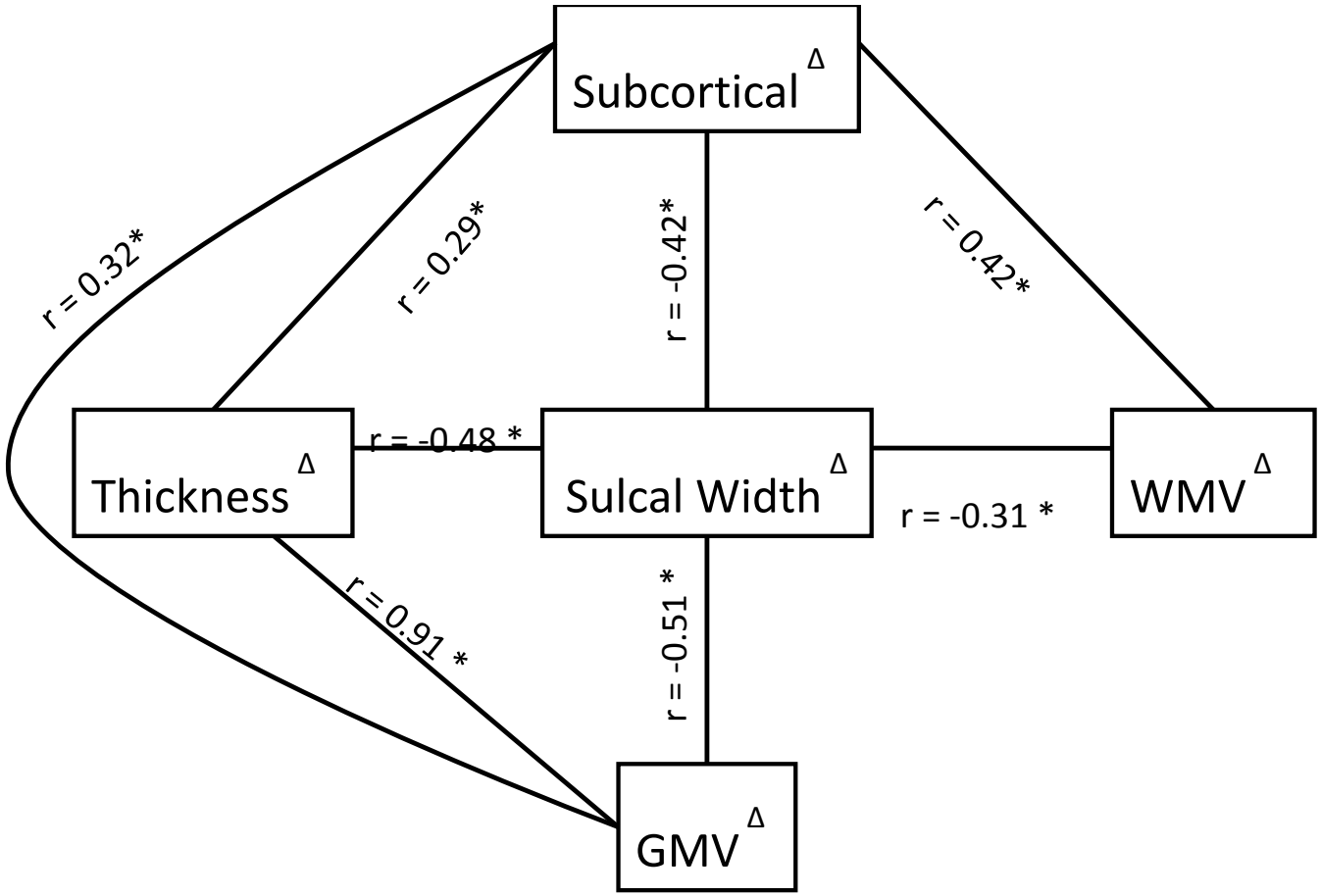

Neuroimaging Update: Summary

- Imaging techniques
- Scan Interpretation
- Disease States:
  - Diagnosis: expanded applications
  - Following disease progression/response
  - Probe neuroreceptor/transmitter integrity
- Healthy States:
  - Investigate cognitive function
  - Neuropsychopharmacology research
  - Correlation with structural imaging, ERP's, EEG